

Time proven **clinical success** of the **SHORT™** implant

Authors Prof. Dr Mauro Marincola, MDS Angelo Paolo Perpetuini, Dr Stefano Carelli, Prof. G. Lombardo, Italy & Dr Vincent Morgan, USA

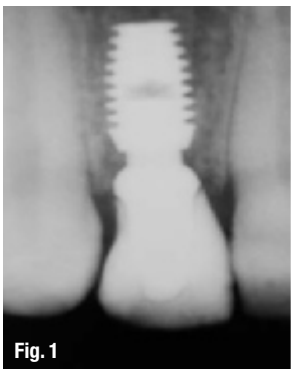

Fig. 1

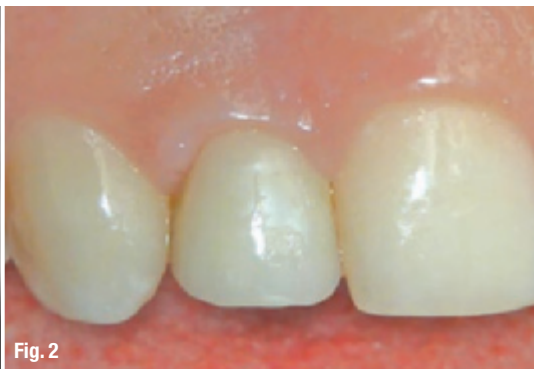

Fig. 2

Introduction

In 1892, Julius Wolff, a German surgeon, published his seminal observation that bone changes its external shape and internal, cancellous architecture in response to stresses acting on it (Wolff's law of bone modelling and remodelling). Therefore, it is a significant engineering challenge to design a short implant that biocompatibly transfers occlusal forces from its prosthetic restoration to the surrounding bone. It requires the understanding and application of many basic biological, mechanical, and metallurgical principles. It is paramount that the entire design of a SHORT™ implant optimises the effectiveness of each of its features within the implant's available surface area and length. Clinical success cannot be met by any single implant design feature such as surface area, but rather requires the appropriate integration of all of its features.

Since an implant's design dictates its clinical and mechanical capabilities, it is scientifically approved that bone healing around a plateau-designed implant is different than the appositional bone (the

bone that is formed by osteoblasts after cell mediated interfacial remodelling) around threaded implants. The plateaued, tapered and root-formed implant body provides for 30 % more surface area than comparably-sized threaded implants. But more importantly, the plateaus provide for an intramembranous-like and faster bone formation (20–50 microns per day), resulting in a unique Haversian bone with clinical capabilities different from the slower forming (1–3 microns per day) of appositional bone around threaded implants.^{1,2} Additionally, the plateaus provide for the transfer of compressive forces to the bone throughout the entire implant.^{3,4}

Description

We analysed the most time-proven short implant on the market that was called the Driskol Precision Implant in the early 1980s, than Stryker and the Bicon Dental Implant from 1993 (Boston, USA).

The Bicon implant has a bacterially-sealed 1.5 degree locking taper (galling or cold welding) connection^{5,6} between the abutment and implant, with the ability for 360 degrees of universal abutment positioning. Having a bacterially-sealed connection eliminates the bacterial flux associated with clinical odours and tastes and reduces inflammation and bone loss consistently.

Another unique characteristic is the sloping shoulder that facilitates the appropriate transfer of occlusal loads to the bone when positioned below the bony crest. But more practically, the sloping shoulder facilitates aesthetic implant restorations,

for it provides space for the interdental papillae with bony support even when an implant is contiguous to another implant or tooth. The sloping shoulder design has been, since 1985, the basis of a sensible biological width and the origin of platform switching.

The 360 degrees of universal abutment positioning provides for the extraoral cementation of crowns; the use of the cementless and screwless Integrated Abutment Crown (IAC™)⁷, the intraoral bonding of fixed bridges, which eliminates the need for cutting, indexing and soldering of bridge frameworks, multiple and easy removal of abutments over time; and the slight aesthetic rotational adjustments during and prior to the seating of a restoration.

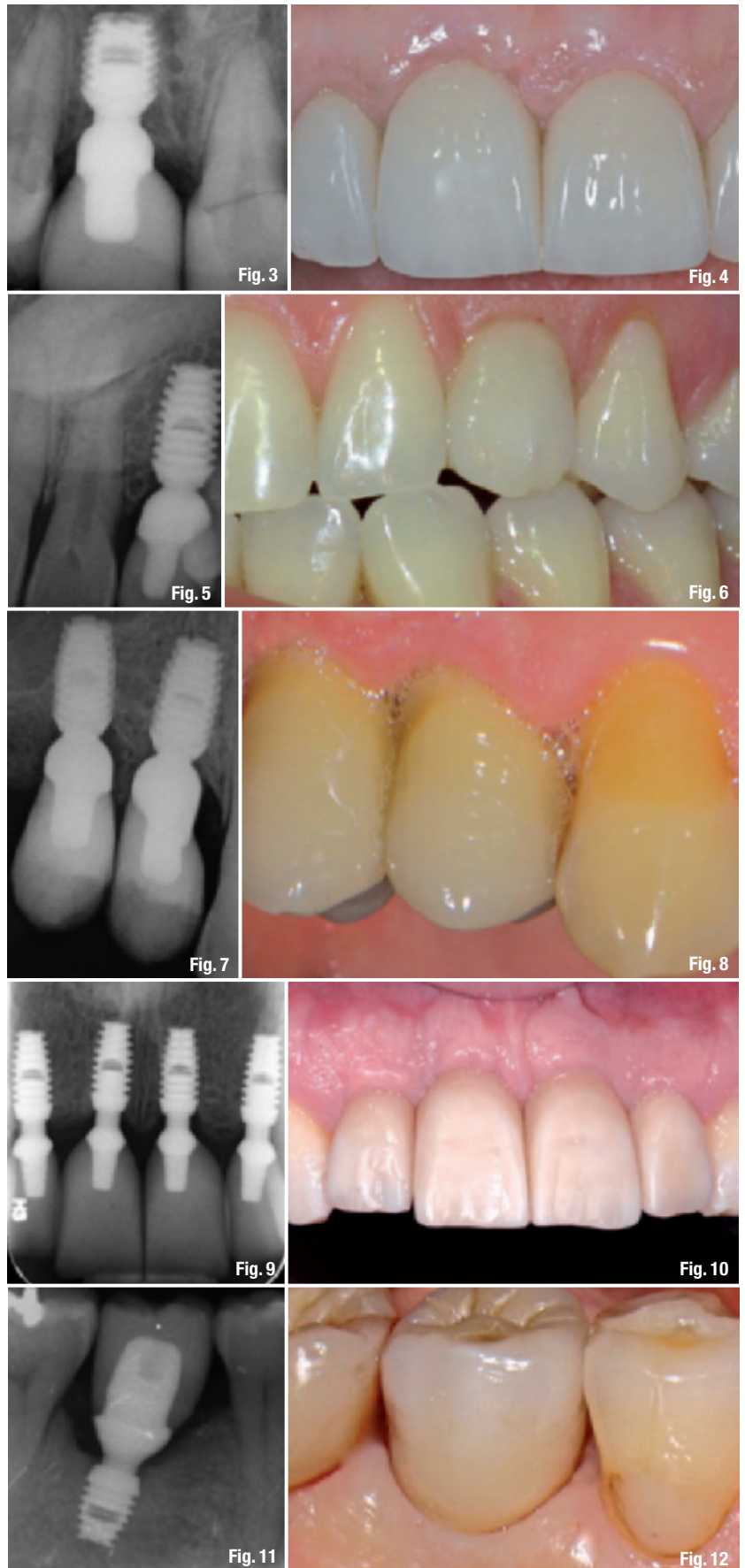
Clinical long-term results

In the following long-term case description we can observe the stability of the crestal bone around the sloping shoulder of the plateau implant. Clinically, the soft tissue contour around the Integrated Abutment Crowns indicates a healthy and stable epithelial tissue.

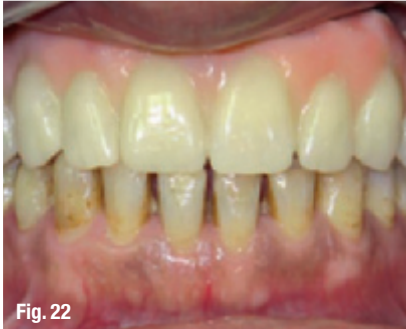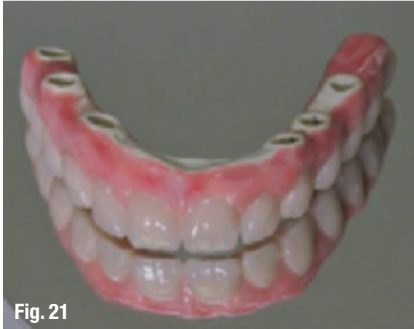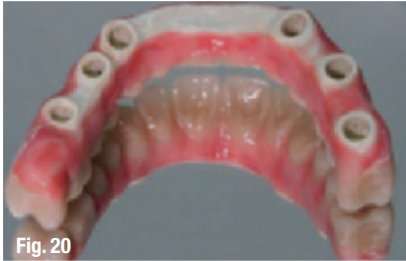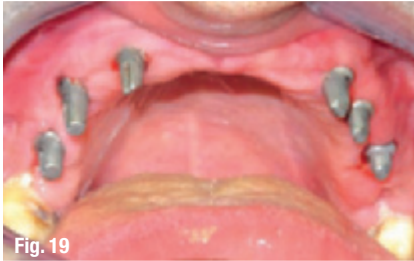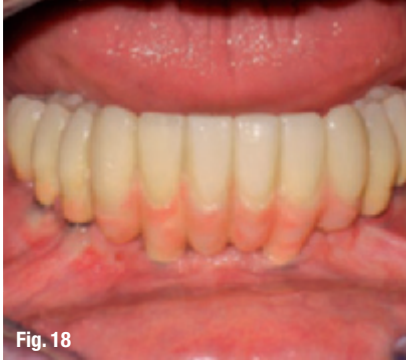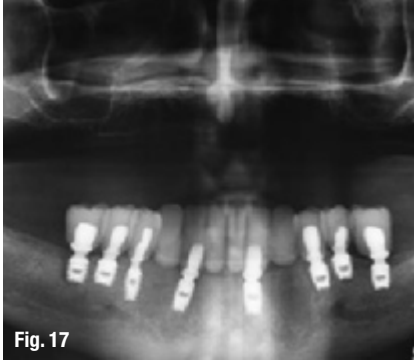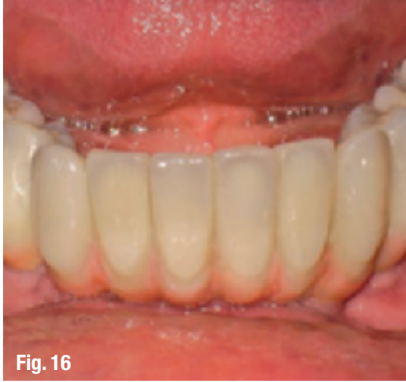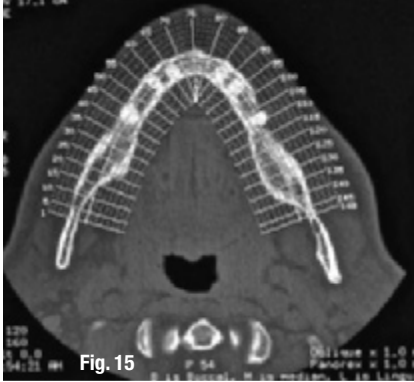
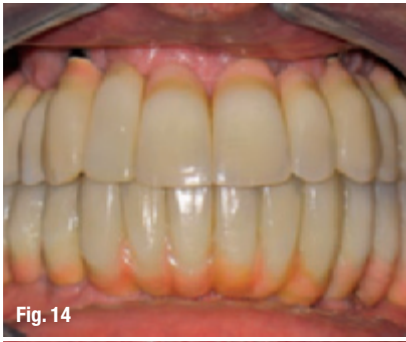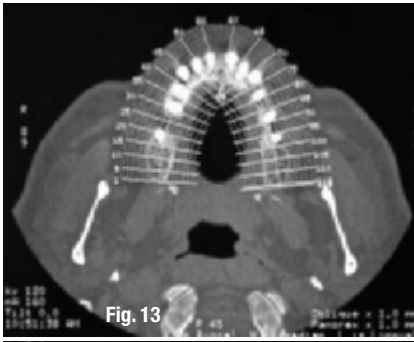
The single-tooth implant is a viable alternative for single tooth replacement.⁸ Single-tooth replacement with endosseous implants has shown satisfactory clinical performance in different jaw locations.

Minimal or no crestal bone resorption is considered to be an indicator of the long-term success of implant restorations. Mean crestal bone loss ranging from 0.12 mm to 0.20 has been reported one year after the insertion of single-tooth implant restorations.⁹ After the first year, an additional 0.01 mm to 0.11 mm of annual crestal bone loss has been reported on single-tooth implant restorations. Some implants demonstrate no crestal bone loss and/or crestal bone gain after insertion of definitive restorations.¹⁰

Crestal bone gain has been documented on immediate and early loaded implants with a chemically modified surface after one year of follow up.¹¹ A six-year prospective study reported that 43.8 % of splinted Morse taper implants experienced some bone gain.¹² Crestal bone gain has been documented around immediately loaded Bicon implants.¹³ The factors that lead to periimplant bone gain in different implant designs have not been investigated. It would be beneficial for the dental practitioner to understand what factors are associated with crestal bone gain on single-tooth implants after crown insertion. Radiographic long-term control also as a clinical observation of the soft tissue structures surrounding the abutment emergence profile can



Figs. 1–12_ Radiographic long-term control helps maintain the implant's bone/soft tissue stability.



provide the clinician with a better understanding of an implant's bone/soft tissue stability (Figs.1–12).

The ideal scenario in modern implant dentistry would be the implant replacement for every missing single tooth (Figs.13 & 14). The single tooth replacement guarantees good aesthetics, consequently to the fact that a single crown that follows all criteria of a natural-looking soft tissue emergence profile can support the soft tissue in order to recreate papillae anatomy.

Another important aspect of single crown restorations on implants is that the patient can follow a better oral hygiene compared to bridge-works. Nevertheless, bridge-works are commonly used as alternatives to single tooth replacement. The reasons are multifactorial, with the cost-benefit factor at first place (Figs.15 & 16). Another significant facet is the atrophic bone situation of the patient, where complicated and expensive bone graft procedures are needed before even thinking of placing single implants.

Alternatively to sophisticated and expensive bridge-works (Figs.17 & 18), cost-effective and simple prosthetic techniques were developed in the last years. One of this techniques, the Fixed on SHORT™, allows to provide the patients with bone atrophies or partial bone deficiencies with a fixed, metal free prosthetic that can be supported by four to six short implants (Figs.19–22).

Conclusion

In this short and synthetic article, the authors like to show the variety of treatment options when implants and prosthetic materials are used with the criteria of long-term crestal bone preservation, recreation and long-term stabilisation of the biological width around the implant/crown and the use of short- and ultra-short implants in all clinical situations. The proper selection of an ultra-short or short implant depends strictly on the implant design which dictates the implant's function.

Editorial note: A complete list of references is available from the publisher.

Figs. 13–16 Bridge-works.
Figs. 17 & 18 Complex bridge-works.
Figs. 19–22 Fixed-on-SHORT™ technique for fixed, metal free prosthetics.

_contact	CAD/CAM
<p>Prof. Dr Mauro Marincola Via dei Gracchi, 285 I-00192 Roma, Italy mmarincola@gmail.com</p>	