

Inconspicuous anterior implant-supported restorations: Combining clinical and laboratory expertise

ADA CERP® Continuing Education Recognition Program

Centre for Advanced Professional Practices (CAPP) is an ADA CERP Recognized Provider. ADA CERP is a service of the American Dental Association to assist dental professionals in identifying quality providers of continuing dental education. ADA CERP does not approve or endorse individual courses or instructors, nor does it imply acceptance of credit hours by boards of dentistry.

CAPP designates this activity for 2 CE Credits



mCME articles in Dental Tribune have been approved by:
HAAD as having educational content for 2 CME Credit Hours
DHA awarded this program for 2 CPD Credit Points

By Dr. Larry R. Holt, USA

The ultimate goal of tooth replacement in the esthetic zone is an inconspicuous transition from dental restoration to the patient's natural, biologic tissues.¹ This transition is evaluated at many levels.² Color and contour of gingiva at the interface must mimic the natural contours and color of adjacent and contralateral teeth.

The dental restoration must match contour and blend seamlessly into the existing dentition. Color matching of final crown must be consistent with existing dentition. (hue, chroma and value). This case study explores the management and correction of a previously treated implant-retained maxillary central incisor.

The patient presented as a healthy, 48-year old female with no contributory health history to prohibit dental treatment. Recent dental history revealed an Ankylos implant to replace tooth #9 had been placed approximately five months prior to this visit. The implant had been uncovered and a temporary abutment was placed.

A ridge lap provisional restoration was fabricated to fit the coronal portion of the abutment. The resultant provisional was not only unesthetic

but also was the source of considerable tissue inflammation and patient discomfort (Figs. 1-3). Patient reported dissatisfaction with the provisional treatment and was seeking a more desirable solution.

Clinical evaluation revealed a well-placed implant with acceptable position both facio-lingually and mesio-distally.³ Additionally, there was good volume of soft tissue and ridge form was ideal.⁴ Surgeon reported that the implant was well-integrated in bone. There was a poorly adapted provisional restoration over an inadequately contoured provisional abutment. Radiograph revealed excess acrylic that extended well into the dental sulcus all the way to the implant platform (Fig. 4). This acrylic did not provide any emergence profile support of transmucosal tissue.

The provisional restoration was poorly adapted to both the abutment and to the ridge crest soft tissue. Intaglio surface was rough and made in such a manner as to create a ridge lap profile. The facial and proximal surfaces of the provisional were fitted over soft-tissue crest. There had been no attempt to modify gingival tissue emergence profile or to create the environment for inconspicuous transition from restoration to biologic tissues.

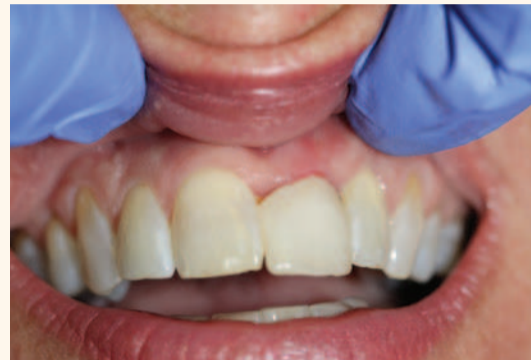

Fig. 1. Initial appearance. (Photos/Provided by Dr. Larry R. Holt)

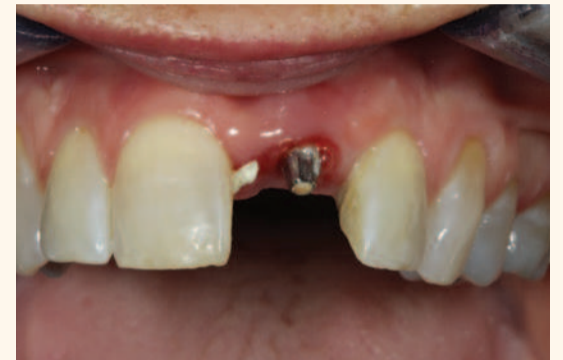

Fig. 2. Provisional removed.

Techniques for managing emergence profile are well-documented in the literature. Interproximal tissues will point and form papillae when appropriate lateral pressure is applied with a temporary abutment when natural teeth are on either side of the implant. The adjacent bone height will dictate the level of the papillae assuming the restoration and its associated abutment properly support them.⁵ Facial contour can be manipulated to create appropriate gingival zenith height by increasing or decreasing facial emergence profile. Increasing the profile will move the gingival zenith apically and reduction of contour will move the crest incisally.⁶

Treatment plan consisted of removal of temporary abutment/provisional

crown, fabrication of a temporary partial denture (Figs. 5,6) and placement of an appropriate temporary abutment that did not retain a provisional crown (Ankylos sulcus former) (Fig. 7).

This sulcus former, as its name implies, would provide soft-tissue emergence profile support. The partial denture was to be placed to avoid interference with the sulcus former when fully seated (Fig. 8). Patient was to be recalled in one-week intervals to evaluate the response to this treatment. Once healed, a final, customized abutment and cementable all-ceramic crown would be delivered.

The plan was followed per previous description. Postoperative visits were uneventful. Patient comfort

was immediate. Tissue health and emergence profile were deemed appropriate at the second week recall visit (Figs. 9, 10).

At a subsequent appointment, the sulcusforming abutment was removed, a closed tray impression coping was placed and an impression (Identium, Kettenbach) was taken for fabrication of final restoration (Figs. 11,12). Appropriate opposing model, bite registrations and facebow accompanied the case to the laboratory. A careful shade map and clinical photography were included.

Clinically, it was determined that this would be a difficult shade because of surface characteristics and maverick colors of the adjacent central incisor. Arrangements were made to have a laboratory technician available at the delivery appointment. Sulcus former and temporary partial were reinserted and patient was dismissed and scheduled for delivery appointment.

All model work was accomplished. The laboratory was given the option of fabricating a custom abutment or customizing a stock abutment. This decision was to be based on the trajectory of the abutment relative to the position of the implant. The placement of the implant was ideal and the use of a lab-modified, stock abutment was selected (0 degree Cercon Balance Abutment, Dentsply Implant).

The contour correlation between the sulcus former and the emergence profile of the stock abutment complement one another. The margins were placed 1 mm subgingivally on facial, mesial and distal. The lingual margin was placed at .5 mm.

Once the abutment was perfected, an all-ceramic crown was fabricated (eMax, Ivoclar). This crown was waxed to full contour, and then the facial was cut back to provide a field into which a customized facial surface could be developed from added porcelain. The wax pattern was invested and pressed. The resultant crown was then modified with additional application of porcelain and was left preglazed in anticipation of chairside staining⁷ (Figs. 13,14).

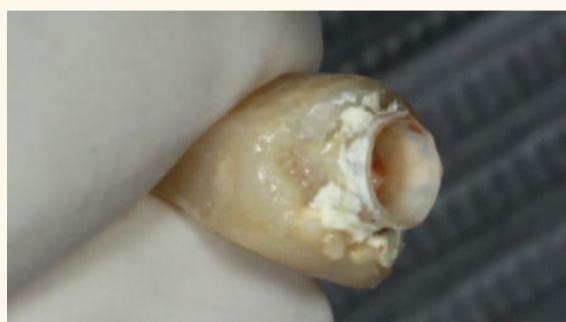

Fig. 3. Provisional lateral intaglio.

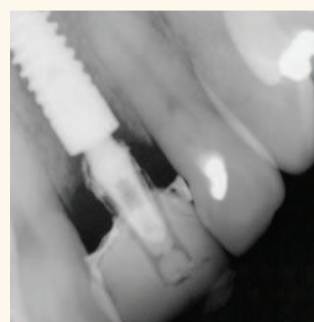

Fig. 4. Provisional abutment and crown.

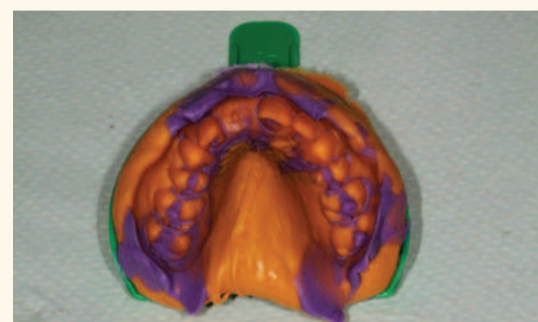

Fig. 5. Impression for temporary partial.

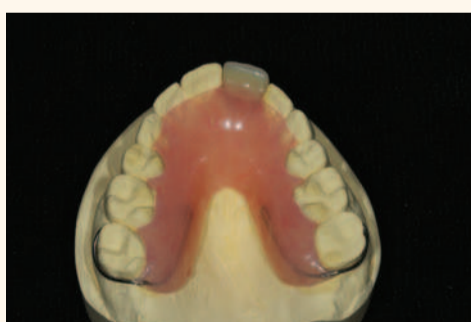

Fig. 6. Temporary partial.

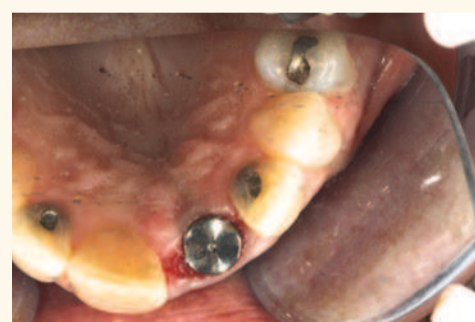

Fig. 7. Ankylos sulcus former.

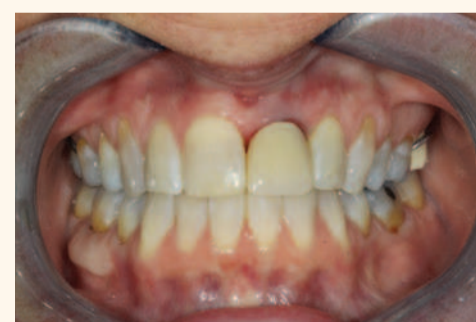

Fig. 8. Temporary partial placed.

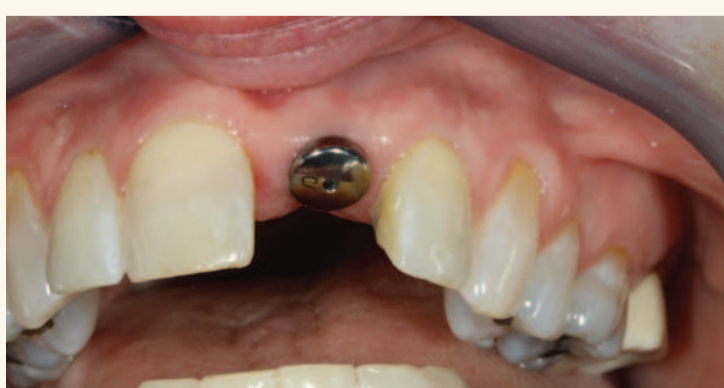

Fig. 9. Tissue healed and emergence profile established at two weeks.

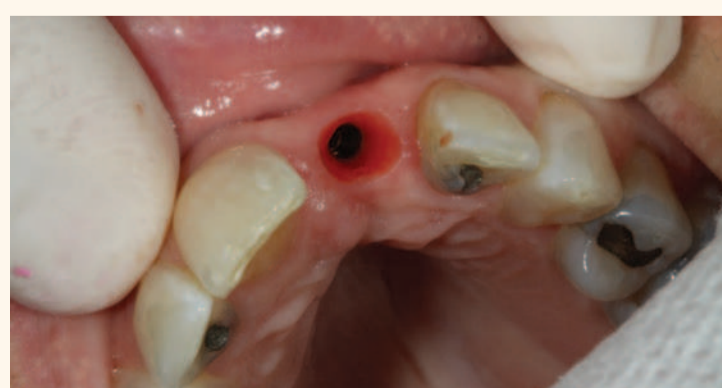

Fig. 10. Sulcus former removed.

◀Page 10

The delivery appointment was uneventful. The lab provided a seating jig that simplified the positioning of the customized abutment (Fig. 15). The abutment was torqued to manufacturer's specification (Figs. 16, 17).

The crown was tried in and adjustments were made to proximal contacts and to occlusion. A dental laboratory technician was enlisted to provide custom chairside staining to perfect the color match. Both patient and clinician were satisfied with the resultant restoration (Fig. 18). The patency of the abutment screw channel was protected with compacted silicone tape, and the restoration was seated with implant cement (Premier Implant Cement, Premier).

Great care was taken to avoid excess cement and to protect the sulcus from any incursion of residual cement extrusion from margins.⁸ A crown-seating jig was provided by the laboratory to be used for removal of excess cement prior to seating of the crown.

Patient was rescheduled at a two-week interval for a final evaluation and photography. She was extremely satisfied with both the esthetics and comfort of the definitive restoration. Clinically, the restoration met the criteria for an inconspicuous restoration (Figs. 19, 20).

Conclusion

Understanding of the soft-tissue interface with implant-supported restorations is critical, fundamental knowledge. All practitioners whose goal is to deliver inconspicuous restorations should practice these concepts. This case study revealed the stark contrast between tissue-management protocols. There is no place in contemporary implant dentistry for ridgelap crowns assuming appropriate pretreatment parameters are met.

The esthetic zone must be evaluated prior to implant placement and any modification of the ridge form

should be taken into consideration well in advance of implant placement surgery.^{9,11} Surgery should be driven by prosthetic requirements. Once surgery is accomplished, it is imperative that restorative clinicians understand how to manipulate the peri-implant soft tissues.

All of this tissue management is critically important. However, then comes fabrication of the final restoration. The abutment must be designed in such a way as to conceal the crown/abutment interface. Furthermore, it must allow for adequate crown thickness to have appropriate strength to withstand mastication forces and still remain retentive. The final contours of the crown must be managed in such a way as to blend into the existing dentition.

This patient did not have a symmetrical arch form. The lateral incisors were not bilaterally symmetrical nor were the incisal edges consistent. Finally, the color match of the restoration, especially a central incisor, must be as identical as possible to the existing dentition. None of these parameters can be accomplished without precise communication and excellent laboratory workflow.

This case was a success based upon all previously described parameters. The gingival contour was essentially mirror image identical to the adjacent central incisor. Papillae were intact.¹² The laboratory was skilled at modification of the abutment so that the margins were concealed within the sulcus. The axial and incisal contours of the abutment provided adequate clearance so that a proper thickness crown could be developed.

This is critical for both esthetics and for long term strength and stability of the definitive restoration. The technician selected the appropriate ingot of ceramic material to serve as substrate for the subsequent application of modifying porcelain and surface staining. Final color matching

could not have been accomplished without skilled hands and eyes of a technician at chairside.

Close communication and strong laboratory relationships, along with appropriate clinical understanding of soft-tissue management, leads to success. The inconspicuous final result of this case could never have been accomplished without strong support from the dental laboratory.

Note: Dr. Holt would like to extend thanks to the exceptional team at Drake Precision Laboratories for providing all laboratory support for this case.

References

1. Kois JC. Predictable single tooth peri-implant esthetics: five diagnostic keys. *Compend Contin Educ Dent.* 2004;25(11):895-900.
2. Lorenzana ER. Soft-tissue risk assessment in esthetic restorative and implant dentistry: smile analysis, gingival esthetics, and dental implant report. *Functional Esthetics & Restorative Dentistry.* 2008;2(3):8-18.
3. Saadoun et al. Selection and ideal tri-dimensional implant position for soft tissue aesthetics. *Prac Perio Aesthet Dent* 1999; 11: 1063-1072.
4. Kinsel, Lamb. Tissue-directed placement of dental implants in the esthetic zone for long-term biologic synergy: A clinical report. *Int J Oral Maxillofac Impl* 2005;20(6):913-922.
5. Lee, Fu, and Wang. Soft Tissue Biotype Affects Implant Success. *Implant Dentistry Volume 20 • Number 3* 38-44.
6. Priest. Esthetic Potential of Single-Implant Provisional Restorations: Selection Criteria of Available Alternatives. *JERD Vol. 18, Number 6, 2006* 326-338
7. Belser UC. Esthetic checklist for the fixed prosthesis. Part II: Biscuit bake try in. In Scharer P, Rinn LA, Kopp FR (Eds). *Esthetic guidelines for restorative dentistry.* pp 188-192. Chicago: Quintessence, 1982.
8. Wadhvani C, Piñeyro A. Technique for controlling the cement for an implant crown. *J Prosthet Dent.* 2009;102(1):57-58
9. Buser D, Martin W, Belser UC. Optimizing esthetics for implant restorations in the anterior maxilla: anatomic and surgical considerations. *Int J Oral Maxillofac Implants.* 2004;19(suppl):43-61.
10. Martin WC, Morton D, Buser D. Pre-operative analysis and pros-

thetic treatment planning in esthetic implant dentistry. In: Buser D, Belser U, Wismeijer D, eds. *ITI Treatment Guide, I: Implant Therapy in the Esthetic Zone: Single Tooth Replacements.* Quintessence Publishing; 2007:9-24.

11. Jivraj S, Chee W. Treatment planning of implants in the aesthetic zone. *Br Dent J.* 2006 Jul 22;201(2):77-89.

12. Tarnow DP, Magner AW, Fletcher P. The effect of distance from the contact point to the crest of bone on the presence or absence of the interproximal dental papilla. *J Periodontol* 1992; 63: 886-995. [DOI](#)



Larry R. Holt, DDS, FICD, graduated from the UNC School of Dentistry in 1978. He was in private practice from 1978-2008. Since 2008, he has been the director of clinical education and research at Drake Precision Dental Laboratories in Charlotte, N.C.

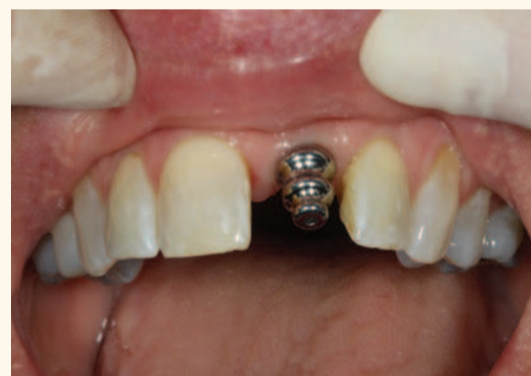

Fig. 11. Ankylos impression coping placed.

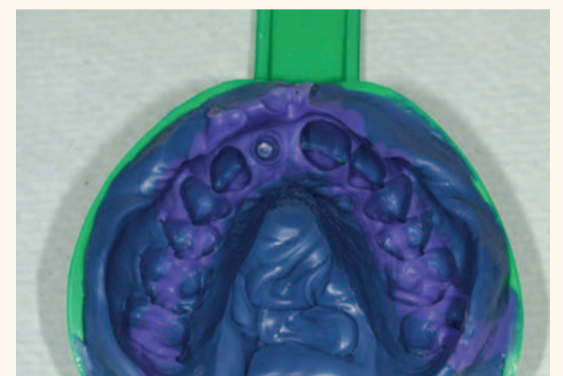

Fig. 12. Final impression.

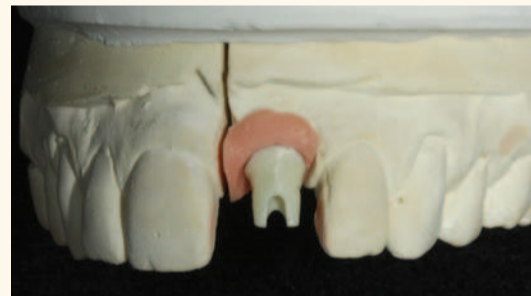

Fig. 13. Abutment with soft tissue moulage.

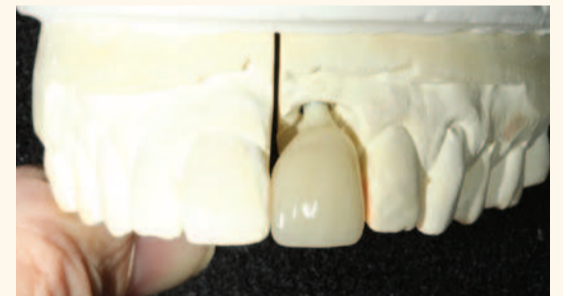

Fig. 14. eMax crown on abutment.

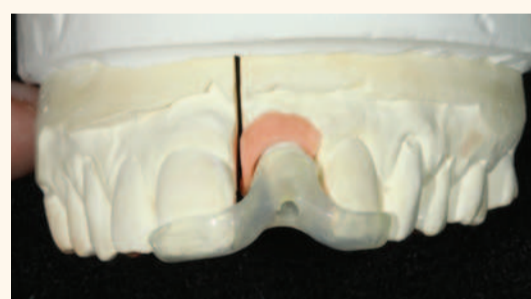


Fig. 15. Seating jig.

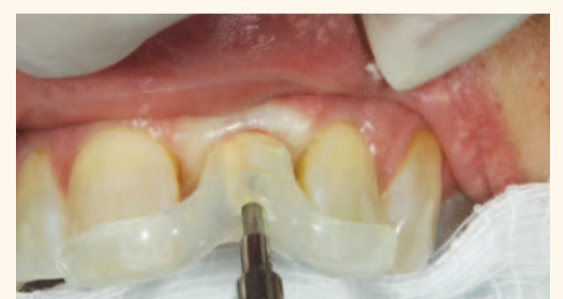

Fig. 16. Placing abutment with seating jig.

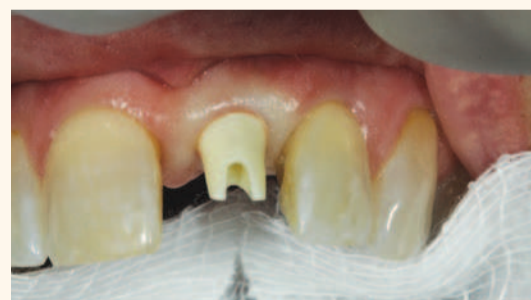

Fig. 17. Abutment torqued and ready for crown seat.

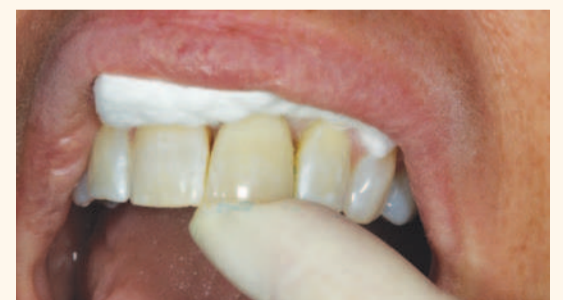

Fig. 18. Seating crown.

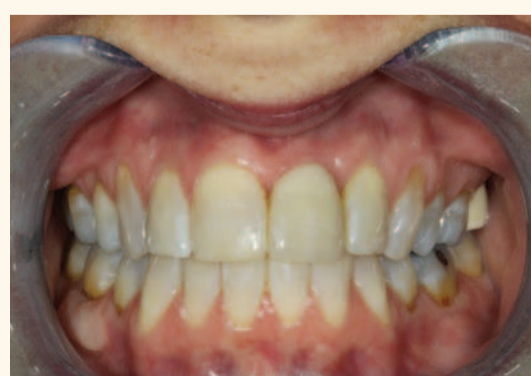

Fig. 19. Final restoration at two weeks.

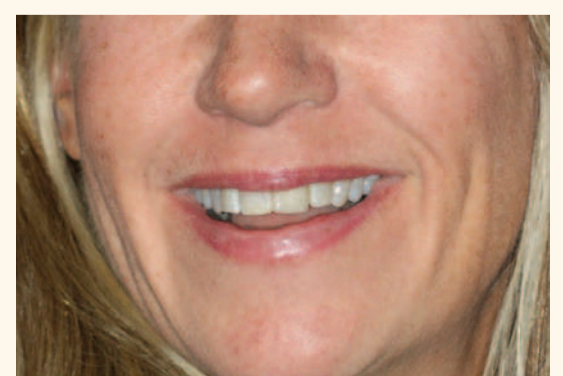

Fig. 20. Patient postoperative smile.

mCME SELF INSTRUCTION PROGRAM

CAPPmea together with Dental Tribune provides the opportunity with its mCME - Self Instruction Program a quick and simple way to meet your continuing education needs. mCME offers you the flexibility to work at your own pace through the material from any location at any time. The content is international, drawn from the upper echelon of dental medicine, but also presents a regional outlook in terms of perspective and subject matter.

Membership

Yearly membership subscription for mCME: 1,100 AED
One Time article newspaper subscription: 250 AED per issue. After the payment, you will receive your membership number and allowing you to start the program.

Completion of mCME

- mCME participants are required to read the continuing medical education (CME) articles published in each issue.
- Each article offers 2 CME Credit and are followed by a quiz Questionnaire online, which is available on www.cappmea.com/mCME/questionnaires.html.
- Each quiz has to be returned to events@cappmea.com or faxed to: +97143686883 in three months from the publication date.
- A minimum passing score of 80% must be achieved in order to claim credit.
- No more than two answered questions can be submitted at the same time
- Validity of the article – 3 months
- Validity of the subscription – 1 year
- Collection of Credit hours: You will receive the summary report with Certificate, maximum one month after the expiry date of your membership. For single subscription certificates and summary reports will be sent one month after the publication of the article.

The answers and critiques published herein have been checked carefully and represent authoritative opinions about the questions concerned.

Articles are available on www.cappmea.com after the publication. For more information please contact events@cappmea.com or +971 4 3616174

FOR INTERACTION WITH THE AUTHORS FIND THE CONTACT DETAILS AT THE END OF EACH ARTICLE.