

Er:YAG & Nd:YAG dual wavelength laser From everyday dentistry to advanced photoacoustic endodontic applications (PIPS)

ADA C-ERP® Continuing Education Recognition Program

Centre for Advanced Professional Practices (CAPP) is an ADA CERP Recognized Provider. ADA CERP is a service of the American Dental Association to assist dental professionals in identifying quality providers of continuing dental education. ADA CERP does not approve or endorse individual courses or instructors, nor does it imply acceptance of credit hours by boards of dentistry.

CAPP designates this activity for 2 CE Credits



mCME articles in Dental Tribune have been approved by:
HAAD as having educational content for 2 CME Credit Hours
DHA awarded this program for 2 CPD Credit Points

By Dr Lawrence Kotlow, Dr Enrico Di-Vito, USA, & Dr Giovanni Olivi, Italy

Introduction

Lasers provide an exciting new technology that allows the dentist the ability to give patients optimal care without many of the “fear factors” found in conventional dental techniques. Used with proper understanding of laser physics, lasers are extremely safe and effective.

Using lasers for caries removal, perio treatment, endodontic treatment, bone management, cutting and shaping, and soft tissue procedures can reduce postoperative discomfort, infection and provide safe, simple in-office treatment. As a result, we can improve our efficiency, expand what we can do, achieve better results and increase production.

Lasers represent a real quantum leap forward in the treatment of our patients, including the paediatric patient. The US Food and Drug Administration (FDA) gave approval for the use of the Er: YAG laser in 1997 for both hard- and soft-tissue procedures. The erbium doped (erbium particles placed within the YAG crystal) crystal of Yttrium-Aluminum-Garnet’s (Er:YAG) development and success has made the treatment of children safer and quicker.

Plainly stated, a laser is a piece of equipment that creates a concentrated monochromatic beam of visible or infrared light that can be absorbed by a specific target. Since then, laser-assisted dental care has changed forever the way dentists can prepare diseased teeth, ablate bone and treat soft tissue abnormalities and disease. An entire new standard of care is becoming a reality.

Lasers and paediatric dentistry are a perfect fit. There are a wide range of hard and soft dental procedures that may be completed using lasers as an alternative to conventional dental care on adults and, especially, children. Many of these procedures may be treatments dentists historically refer out to other specialists; however, if you understand and use your laser efficiently, you will discover that many of these are procedures that every dentist can easily complete.

The question that is often the major concern and barrier to investing in lasers is the how this investment will pay for itself, more recently described as return on your investment (ROI). Will it pay for itself? We prefer to speak of this as the secondary effect. If you understand your laser, it will easily pay premiums on your investment, and the cost factor becomes a non-issue.

The purchasing of lasers is an investment, not an expense, for any dental practice.

Lasers represent a fundamental change in the entire way dentistry has been taught. We can now rethink and often modify G.V. Black’s principle of extension for prevention with the concept of minimally invasive micro-dentistry. We need to understand that laser dentistry is one portion of an entire new way of practicing conservative, pain-free dentistry.

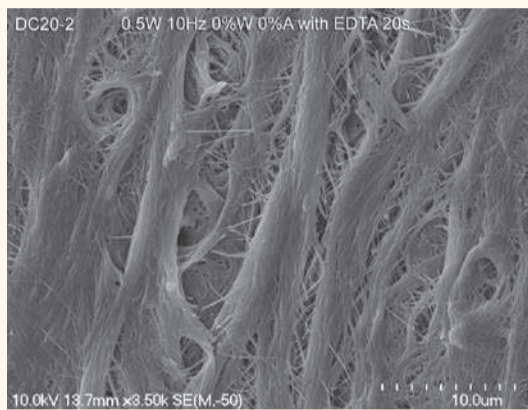
The laser that we call the “all-purpose” laser is the Lightwalker Er:YAG & Nd:YAG laser, manufactured by Fotona and distributed in the United States by Technology4Medicine. The Er:YAG produces its effect at 2,940 nm and has as its primary tissue target water and hydroxyapatite. It is very safe, relatively quiet, eliminates the smells and vibrations associated with the dental handpiece and, most importantly, is much more comfortable for the patient, significantly reducing the need for local anaesthesia.

The use of the new generation erbium lasers for repair of incipient hard-tissue disease allows the dentist to provide a stress-free means of restoring teeth in a minimally invasive manner, most often with no shot and no numb lip, without the need for any local anaesthetics.

The erbium laser can be used for restoring primary and permanent teeth, eliminating or reducing the amount of local anaesthetics. In most cases, the patient will not require numbing for Class^{1, 2} (sometimes),^{3, 4, 5, 6} restorative procedures using bonded restorative materials. Using the concept of minimally invasive restorative procedures, the Er:YAG laser allows the operator to

remove only diseased tissue and thus preserves much more of the healthy unaffected tooth.

In cases where alloy is preferred, the laser’s analgesia effect may also allow the dentist to create a restorative preparation using a conventional hand-



Figs. 1 & 2: Representative sample images of root canal dental walls irrigated with 17 per cent EDTA and PIPS for 20 seconds. (Photos courtesy of Technology4Medicine)





Fig. 3: Representative sample image of root canal dental walls irrigated with 17 per cent EDTA and PIPS for 20 seconds.

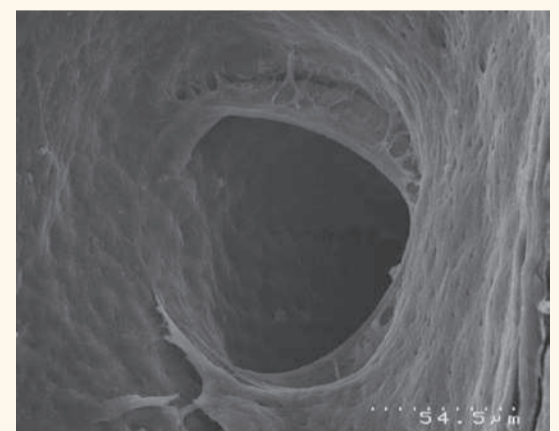


Fig. 4: SEM image of clean lateral canal.

piece that is not meant for bonding. The erbium laser is effective because of its effect on its target, water within the tooth structure. This effect occurs when the laser heats up water within the target tissue, causing it to create small microscopic explosions (photothermal followed by photoacoustic effects). When applied to soft tissue, bone or teeth and cavities, the explosions then cause the areas to be vaporized.

Er:YAG laser 2,940 nm: Soft-tissue procedures

There is a wide array of soft-tissue procedures that are able to be completed using the all-purpose laser: maxillary and mandibular frenum revisions, lingual frenum revisions, treatment of pericoronar pain or infection, removal of hyperplastic tissue because of drugs or poor oral care in orthodontic patients, biopsies, treatment of aphthous ulcers and herpes labialis, pulpotoomies, removal of impacted teeth and in adults apicoectomies and bone recontouring.

Pulpotomies

Parents often express concern about the need to take radiographs because of the nature of X-rays and their possible side effects on their child’s overall health. They question the use of alloys because of the chemical makeup of the alloy. Whether these should be a real concern in today’s dental care is open to debate, depending on your individual beliefs. There are also concerns by many, although not as loudly, about the effect of various pulpotomy procedure medicaments

used in pulpotomy procedures such as formocresol.

Lasers provide a safe, non-chemical effective alternative treatment for pulpotoomies. During eight years, post-treatment results on more than 4,000 pulpotoomies using the erbium (2,940 nm) laser provides ample evidence that this method is both effective and safe for children without the need for introducing chemicals or using electrosurgery methods.

When the final result of orthodontic positioning of the front teeth results in gingival hypertrophy, the laser can be a useful tool to increase crown length and give the patient a more aesthetic smile. This may often be accomplished without the need for local anaesthesia. Patients who have medically induced hyperplastic tissue, such as patients requiring dilantoin, can also have their tissue reduced and reshaped with the erbium.

In addition to the many examples described in this article, lasers can be used for additional procedures not usually required in paediatric dentistry, such as revisions of the abnormal mandibular frenum, often avoiding the need for soft-tissue grafts, crown-lengthening procedures where bone requires recontouring, apicoectomies, removal of bony exostoses, removal of third molar impactions, removal of root remnants, incising and draining soft-tissue infections, advanced periodontal treatments and the latest in advanced endodontic treatment

via photoninduced photoacoustic streaming.

Photoacoustic endodontics using PIPS

The goal of endodontic treatment is to obtain effective cleaning and decontamination of the smear layer, bacteria and their byproducts in the root canal system. Clinically, traditional endodontic techniques use mechanical instruments, as well as ultrasonic and chemical irrigation, in an attempt to shape, clean and completely decontaminate the endodontic system but still fall short of successfully removing all of the infective microorganisms and debris. This is because the complex root canal anatomy and the inability for common irrigants to penetrate into the lateral canals and the apical ramifications. It seems, therefore, appropriate to search for new materials, techniques and technologies that can improve the cleaning and the decontamination of these anatomical areas.

Among the new technologies, the laser has been studied in endodontics since the early 1970s¹⁻³ and has become more widely used since the '90s.⁴⁻⁶

Different wavelengths have been shown to be effective in significantly reducing the bacteria in the infected canals, and important studies have confirmed these results in vitro.⁷ Studies reported that near infrared




Fig. 5: New tapered tip design for this technique.

◀Page 12

laser are highly efficient in disinfecting the root canal surfaces and the dentinal walls (up to 750 microns the diode 810 nm and up to 1 mm the Nd:YAG 1,064 nm). On the other hand, these wavelengths did not show effective results in debriding and cleansing the root canal surfaces and caused characteristic morphological alterations of the dentinal wall. The smear layer was only partially removed and the dentinal tubules primarily closed as a result of melting of the inorganic dentinal structures.^{5,8}

Other studies reported the ability of the medium infrared laser in debriding and cleaning root canal walls.^{9,10} The bacterial load reduction after erbium laser irradiation, demonstrated high on the dentin surfaces, but low in depth of penetration because of the high absorption of laser energy on the dentin surface.⁷ Also the laser activation of commonly used irrigants (LAI) resulted in statistically more effective removal of debris and smear layer in root canals compared with traditional techniques (CI) and ultrasound (PUI).^{11, 12} Additionally the laser activation method resulted in a strong modulation in reaction rate of NaOCl significantly increasing production and consumption of available chlorine in comparison to ultrasound activation.¹³

A recent study has reported how the use of an Er:YAG laser, equipped with a newly designed radial and stripped tip, in combination with 17 per cent EDTA solution, using very low pulse duration (50 microseconds) and low energy (20 mJ) resulted in effective debris and smear layer removal with minimal or no thermal damage to the organic dentinal structure through a photoacoustic technique called photon induced photoacoustic streaming or "PIPS."^{14, 15} Also the same photoacoustic protocol in combination with 5.25 per cent sodium hypochlorite solution has been investigated and shown to reduce the bacterial load and its associated biofilm in the root canal system three dimensionally.¹⁶

Other similar studies are in progress for publication and the results are promising and suggest a three-dimensional positive effect of this laser-activated decontamination (LAD) method.

The purpose of this article is to present briefly the experimental background of this laser technique and to introduce the clinical protocol.

Scientific background

The microphotographic recording of the LAI studies suggested that the erbium lasers used in irrigant-filled root canals generate a streaming of fluids at high speed through a cavitation effect.¹⁷ The laser thermal effect generates the expansion-implosion of the water molecules of the irrigant solution, generating a secondary cavitation effect on the intracanal fluids. To accomplish this streaming, it is suggested the fiber be placed in the middle third of the canal, 5 mm from the apex and stationary.¹⁸ This concept greatly simplifies the laser technique, without the need to reach the apex and to negotiate radicular curves.

Also, the recorded video of the new technique, PIPS, showed a strong agitation of the liquids inside the canals. It differs from the already cited LAI technique by activating the irrigant solutions in the endodontic system through a profound photoacoustic and photomechanical phenomena. The use of low energy (50 microsecond pulse, 20 mJ) at 15 Hz, 0.3 W average power, or less) generates only

a minimal thermal effect. The study with thermocouples applied to the radicular apical third revealed only 1.2 °C of thermal rise after 20 seconds and 1.5 °C after 40 seconds of continuous radiation.¹⁴

When the erbium laser energy is delivered at only 50 microsecond pulse duration through a special designed tapered and stripped 400 microns tip (Fotona LightWalker, Technology-Medicine), it produces a large peak power of 400 watts when compared to a longer pulse duration. Each impulse, absorbed by the water molecules, creates a strong "shock wave" that leads to the formation of an effective streaming of fluids inside the canal while also limiting the undesirable thermal effects seen with other methodologies. The placement of the tip in the coronal portion only of the treated tooth allows for a more minimally enlarged canal preparation with less thermal damage as seen with those techniques placed into the canal system.

The root canal surfaces irrigated with 17 per cent EDTA and laser activated for 20 seconds showed exposed collagen matrix, opened tubules and the absence of smear layer and debris (Figs. 1-3). The rinsing with 5.25 per cent sodium hypochlorite and laser irradiation for 20 seconds produced a strong activation of the solution, as reported by Macedo,¹³ improving the disinfecting action of the sodium hypochlorite.¹⁶ The disinfecting action of PIPS is very effective both on the root surface, the lateral canals and the dentinal tubules, as confirmed with SEM and confocal studies (Fig. 4).

The profound and distant effect of PIPS eliminates the need to introduce the tip into the root canal system. Unlike traditional laser techniques requiring placement of the tip 1 mm from the apex, or even 5 mm from the apex as proposed for LAI⁸, the PIPS tip is placed in the coronal portion of the pulpal chamber only and left stationary allowing the photoacoustic effect to spread into the openings of each canal. A new tip

design consisting of a 400-micron diameter, 12 mm long, tapered end is used for this technique (Fig. 5). The final 3 mm of coating is stripped from the end to allow for greater lateral emission of energy compared to the frontal tip.

This mode of energy emission allows for improved lateral diffusion with low energy and enhanced photoacoustic effect.

Discussion

Laser irradiation is a common technique used in endodontics to improve both the cleaning, the debriding and disinfection of the root canal system. Many wavelengths and protocols are used. Near infrared lasers are used for the three-dimensional decontamination of the endodontic system. Nd:YAG and diode lasers use thermal energy to destroy bacteria. Observations reveal a certain grade of thermal injury to the root canal surface and create a typical morphological damage. Moreover, they are not able to thoroughly remove the smear layer.

On the contrary, erbium lasers are used for their effective smear layer removal while their bactericidal activity is limited to the root surface. The placing of the tip close to the apex and its back movement during the activation process is related to the risk of apical perforation, ledging and surface thermal damage, because of the ablation ability of this wavelength. Also a combination of the near and medium infrared lasers has been proposed. A technique, called twilight endodontic treatment (TET), uses the erbium laser energy first, to clean the root canal surface and remove the smear layer, and the Neodimium:YAG laser second, used in dry mode as the final disinfecting step. All these techniques utilize traditional tips and fibres placed into the canal, close to the apex (1 mm) with all the corresponding thermal disadvantages observed in long, narrow and curve canals.

The erbium lasers are also used as a medium of activation of commonly

used irrigants (LAI), avoiding the risk of thermal damage, while increasing the cleaning and disinfecting activity of the fluids. PIPS, in particular, reduces all these risks and disadvantages, thanks to the position of the tip in the coronal orifice only and to the use of minimally ablative energy levels of 20 mJ or less.

The findings of our studies demonstrated that PIPS technique resulted in a safe and effective debriding and decontaminating the root canal system. Our clinical trials showed that PIPS technique greatly simplifies root canal therapy while facilitating the search for the apical terminus, debriding and maintaining patency. As a result of the efficacy of PIPS the final size required for canal shaping can be significantly reduced, often to a size 25/04, allowing for a more minimally invasive and biomimetic preparation which can then be obturated three dimensionally.

Conclusion

Lasers are an extremely versatile addition to the dental practice and can be used in many instances instead of the conventional methods employed by the vast majority of dentists. Incorporating a laser in the dental practice should be viewed as an investment rather than a cost. When used with a good knowledge of laser physics, training and safety, lasers provide our patients a new standard of dental care.

References

- [1] Weichman JA, Johnson FM. Laser use in endodontics. A preliminary investigation. *Oral Surg Oral Med Oral Pathol.* 1971 Mar;31(3):416-20.
- [2] Pini R, Salimbeni R, Vannini M, Barone R, Clauser C. Laser dentistry: a new application of excimer laser in root canal therapy. *Lasers Surg Med.* 1989;9(4):352-357.

1989;9(4):352-357.

- [3] Shirasuka T, Wakabayashi H, Debari K, Kodaka T, Ahmed S, Matsumoto K. Morphologic changes in human tooth enamel by continuous-wave Nd:YAG laser irradiation. *Showa Shigakkai Zasshi.* 1990 Jun;10(2):206-215.
- [4] Myers TD. Lasers in dentistry. *CDS Rev.* 1991 Sep;84(8):26-29.
- [5] Gutknecht N, Behrens VG. Instrumentation of root canal walls with Nd:YAG laser. *ZWR.* 1991 Oct;100(10):748-750, 752, 755.
- [6] Stabholz A, Moshonov J, Rotstein I. Lasers in endodontics. *Rev Belge Med Dent.* 1992;47(4):9-15. Review.
- [7] Schoop U, Kluger W, Moritz A, Nedjelic N, Georgopoulos A, Sperr W. Bactericidal effect of different laser systems in the deep layers of dentin. *Lasers Surg Med.* 2004;35(2):111-116. [DOI](#)

The full list of references is available from the publisher.

Dr Lawrence Kotlow, DDS, has been in private dental practice in Albany, NY, since 1974. He is board certified in pediatric dentistry. He is a recognized standard proficiency course provider for the Academy of Laser Dentistry.

Dr Enrico DiVito, DDS, is an Adjunct Professor at the Arizona School of Dentistry and Oral Health. He is in private practice at the Arizona Center for Laser Dentistry in Scottsdale, AZ, in conjunction with MDATG research group.

Dr Giovanni Olivi, MD, DDS, is a Professor of endodontics at the University of Genoa School of Dentistry, where he is director for the Laser in Dentistry Master Course with Prof. S. Benedicenti. He is in private practice in Rome, Italy.

mCME SELF INSTRUCTION PROGRAM

CAPPmea together with Dental Tribune provides the opportunity with its mCME - Self Instruction Program a quick and simple way to meet your continuing education needs. mCME offers you the flexibility to work at your own pace through the material from any location at any time. The content is international, drawn from the upper echelon of dental medicine, but also presents a regional outlook in terms of perspective and subject matter.

Membership

Yearly membership subscription for mCME: 1,100 AED
One Time article newspaper subscription: 250 AED per issue. After the payment, you will receive your membership number and allowing you to start the program.

Completion of mCME

- mCME participants are required to read the continuing medical education (CME) articles published in each issue.
- Each article offers 2 CME Credit and are followed by a quiz Questionnaire online, which is available on www.cappmea.com/mCME/questionnaires.html.
- Each quiz has to be returned to events@cappmea.com or faxed to: +97143686883 in three months from the publication date.
- A minimum passing score of 80% must be achieved in order to claim credit.
- No more than two answered questions can be submitted at the same time
- Validity of the article – 3 months
- Validity of the subscription – 1 year
- Collection of Credit hours: You will receive the summary report with Certificate, maximum one month after the expiry date of your membership. For single subscription certificates and summary reports will be sent one month after the publication of the article.

The answers and critiques published herein have been checked carefully and represent authoritative opinions about the questions concerned.

Articles are available on www.cappmea.com after the publication. For more information please contact events@cappmea.com or +971 4 3616174

FOR INTERACTION WITH THE AUTHORS FIND THE CONTACT DETAILS AT THE END OF EACH ARTICLE.