

Surgical management of peri-implantitis

Specialist Periodontist, Dr Jeremy Vo, explains how he has embraced AIR-FLOW® technology in the management of Peri-Implantitis

By Dr Jeremy Vo

Surgical intervention is often required in the treatment of advanced peri-implantitis lesions. Peri-implantitis is defined as an inflammatory process around an implant, with soft tissue inflammation and loss of supporting marginal bone.¹

The aim of surgical therapy is to allow access for the decontamination of implant surfaces which have been exposed to oral biofilms. Several approaches for implant decontamination have been described and can be broadly categorised to include mechanical, chemical and laser instruments.²

Mechanical removal of hard and soft deposits can be achieved with rubber cups, curettes, and/or ultrasonic devices.² Curettes of different materials have been manufactured, specifically for the debridement of implant surfaces. These materials include

steel, titanium, carbon-fiber, Teflon and plastic. Ultrasonic devices with polyetheretherketone (PEEK)-coated tips are also specific for implant surfaces. A more aggressive approach has been proposed which involves intentional removal of the implant threads. This is known as 'implantoplasty' and the aim is to produce a polished, smooth collar which better supports oral hygiene compared with the original rough surface of the implant.

Chemical decontamination is aimed at disinfecting the implant surface by direct application during surgery.³ Following elevation of the soft tissues, the implant surface can be rinsed with several different substances including chlorhexidine, sodium chloride, hydrogen peroxide and citric acid. Unfortunately, no chemical agent has shown superior results when compared with others.⁴

Laser decontamination - includ-

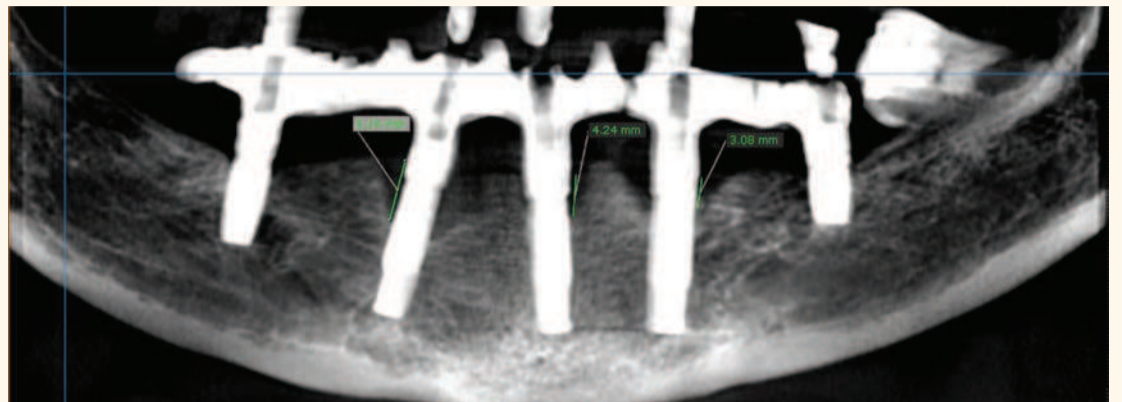


Figure 1. Radiographic assessment at baseline.

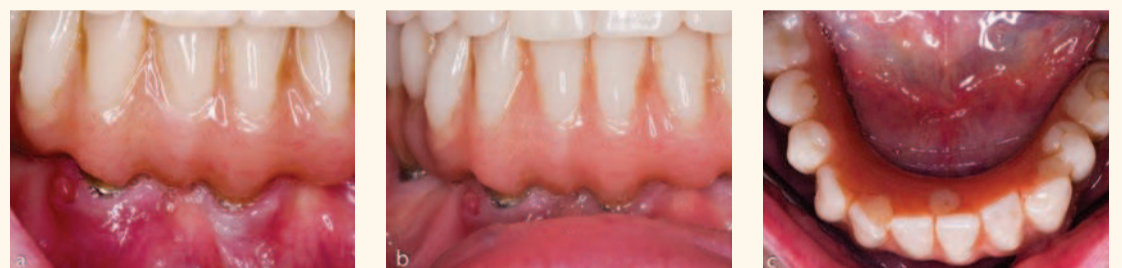

Figure 2a-c. Pre-operative clinical photographs.

ing the use of Er:YAG and CO₂ lasers - have also been utilised during surgery in an attempt to improve clinical outcomes. The evidence is, however, weak and has not shown significant improvement when compared with conventional mechanical therapy.⁵

There are 3 main approaches for surgical intervention including:³

Access surgery

The primary aim of access surgery is to decontaminate the implant surface.³ Commonly, intrasulcular incisions will allow the conservation of the soft tissues around the implant once the mucoperiosteal flaps are elevated. Inflamed peri-implant tissues are degranulated and the implant surface is decontaminated. A clinical study with 5 years follow up reported complete resolution of advanced peri-implantitis lesions in 42% of implants and 63% survival of implants.⁶

Resective surgery

This surgical technique allows implant decontamination to take place; but rather than conserving soft tissues, a reverse beveled incision combined with osteoplasty reduces the pocket depths around the implant.³ As a result, the neck of the implant is usually left exposed to the oral cavity and therefore, this technique is only suggested for implant defects in non-aesthetic areas. The 2-year outcome of resective peri-implantitis surgery found complete resolution of clinical signs of disease in almost 60% of implants.⁷

Regenerative surgery

Regenerative surgery is aimed at improving hard tissue integration around the implant (re-osseointegration) as well as minimising recession of the peri-implant mucosa.³ Following mucoperiosteal flap elevation, the implant surface is decontaminated and the intrabony defect is degranulated. Various approaches to bone grafting have been described. Bone substitute materials such as Bio-Oss® (Geistlich Biomaterials) can be used to fill the intrabony defect which is then covered with a resorb-

able or nonresorbable membrane. A 4-year clinical study found significant reductions in probing pocket depth and radiographic defect fill with a regenerative technique involving Bio-Oss® and Bio-Gide®.⁸

The clinical approach

The development of biofilm on the implant surface plays a significant role in the initiation and progression of peri-implant diseases. The bacterial microflora is composed predominantly of Gram-negative anaerobes and is similar to microflora found around teeth with severe periodontitis.⁹ Unfortunately, in the management of peri-implantitis, no definitive gold standard has been identified for implant decontamination. Implant surface roughness and irregularities can enhance bacterial attachment and prevent adequate instrumentation. The tips of the curettes are often too large to reach the deeper parts of the thread.

Recently, a powered air-abrasive system utilising Erythritol (a sugar substitute) has been proposed as an effective method of biofilm removal from the implant surface that is safe on hard and soft tissues (EMS AIR-FLOW® EL-308/A; Electro Medical Systems (EMS)).¹⁰ The abrasiveness of Erythritol is low and it does not cause extensive damage to the surface topography of the implant compared with the use of conventional steel curettes or ultrasonics. Furthermore, in vitro data suggests that it has an antimicrobial effect.¹¹

Once the implant surface has been decontaminated, the morphology of the bony defect may help determine the most suitable surgical approach. Generally, if the defect is circumferential with intact bony walls, or has an intrabony component, the use of a regenerative approach will provide improved clinical outcomes. On the other hand, if the defect is suprabony or the implant presents with some degree of buccal dehiscence, an apically repositioned flap would be indicated in these non-aesthetic areas.



All solutions for a perfect smile

SGS Dental Implants made from biocompatible material, we have solutions fitting to all of the dental implant techniques.

Strongest point of our products are the high-technology coating and the immediate loadability. Our implants show excellent results with osseointegration.

Why choose us?

- + Swiss quality
- + Lifetime warranty
- + Premium surface
- + Friendly support



www.dme-medical.com Tel: +971-6-5308055

SGS Dental Implant System Holding - Zn
Talhofstrasse 9, CH -9000 St. Gallen, Switzerland

SGS International Kft./Ltd. European Logistic Center
H-1047 Budapest, Károlyi István u. 1-3. | Tel: +36 1 328 0427 | www.sgs-dental.com

◀Page 20

The following case study illustrates a protocol that was used to treat advanced peri-implantitis. The case was treated successfully with a 6-month follow-up. Success was defined by a reduction in probing pocket depths (ffi4mm), along with a reduction of soft tissue redness and bleeding on probing.

Case Study: Regenerative approach for treatment of peri-implantitis

A 70-year-old female was referred for advanced peri-implantitis in the mandible. She presented complaining of pain and she also noticed discharge from one of the anterior implants. Her medical history was non-contributory and she was a non-smoker.

Clinical examination revealed 5 implants in the mandible supporting a fixed full arch reconstruction. Probing pocket depths were of the order of 8-9mm around 3 of the anterior implants. The distal implants had normal probing depths. CBCT imaging revealed an intrabony component of 6.1mm for the implant in the 43 position, 4.2mm at the 41 implant and 3.1 at the 33 implant.

A preparatory phase was carried out, including assessment of oral hygiene and non-surgical implant decontamination in 1 session. After 6 weeks, the patient underwent surgical treatment. This comprised of full thickness mucoperiosteal flaps being raised and the chronic inflammatory tissue removed from the defects around the 3 implants with the use of teflon curettes. The implant surface was then decontaminated using EMS AIR-FLOW® technology with very fine erythritol powder (EMS AIR-FLOW® PLUS Powder). The implants were also irrigated and cleansed with saline-soaked cotton foam.

A crater shaped defect was present around all the implants at the proximal and lingual surfaces, however the implants had a dehiscence on the buccal aspect. The craters were filled with BioOss granules (Geistlich) and Bio-Gide was placed to cover the defects. Lastly, the flaps were repositioned and secured with mattress and sling sutures. Systemic antibiotics were administered postoperatively. The full arch prosthesis was re-issued at the completion of surgery. Clinical parameters and radiographic examinations were performed at 3 and 6 months. At both intervals, there was resolution of the clinical parameters for all 3 implants, including plaque index, bleeding on probing and probing pocket depth. At these visits, non-surgical maintenance was carried out, including oral hygiene reinforcement and removal of biofilm via EMS AIR-FLOW® technology and EMS AIR-FLOW® PLUS Powder.

References

1. Lindhe J, Meyle J. Peri-implant diseases: Consensus Report of the Sixth European Workshop on Periodontology. J Clin Periodontol 2008;35:282-285.
2. Figuero E, Graziani F, Sanz I, Herrera D, Sanz M. Management of peri-implant mucositis and periimplantitis. Periodontol 2000 2014;66:255-273.
3. Renvert S, Polyzois IN. Clinical approaches to treat peri-implant mucositis and peri-implantitis. Periodontol 2000 2015;68:369-404.
4. Claffey N, Clarke E, Polyzois I, Renvert S. Surgical treatment of peri-implantitis. J Clin Periodontol 2008;35:316-332.
5. Schwarz F, Sahm N, Iglhaut G, Becker J. Impact of the method of surface debridement and decontamination

on the clinical outcome following combined surgical therapy of peri-implantitis: a randomized controlled clinical study. J Clin Periodontol 2011;38:276-284.

6. Heitz-Mayfield LJ, Salvi GE, Mombelli A, et al. Supportive peri-implant therapy following antiinfective surgical peri-implantitis treatment: 5-year survival and success. Clin Oral Implants Res 2016.

7. Serino G, Turri A. Outcome of surgical treatment of peri-implantitis: results from a 2-year prospective clinical study in humans. Clin Oral Implants Res 2011;22:1214-1220.

8. Schwarz F, Sahm N, Bieling K, Becker J. Surgical regenerative treatment of peri-implantitis lesions using a nanocrystalline hydroxyapatite or a natural bone mineral in combination with a collagen membrane: a four-year clinical follow-up report. J Clin Periodontol 2009;36:807-814.

9. Leonhardt A, Renvert S, Dahlén G. Microbial findings at failing implants. Clin Oral Implants Res 1999;10:339-345.

10. Taschieri S, Weinstein R, Del Fabbro M, Corbella S. Erythritol-enriched air-polishing powder for the surgical treatment of peri-implantitis. The

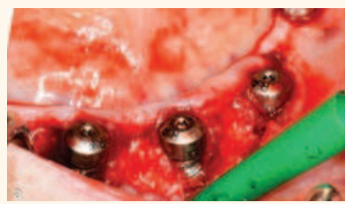


Figure 3a-c. Sequence of surgical therapy: Flap elevation revealing chronic inflammatory tissue; Debridement and decontamination of implant surface; and Defects filled with Bio-Oss and covered with Bio-Gide and mucoperiosteal flaps are repositioned and sutured.

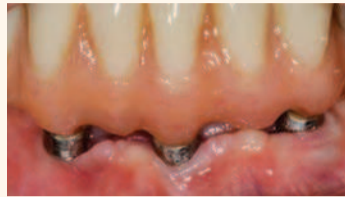
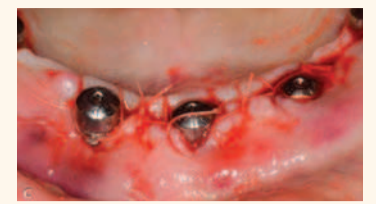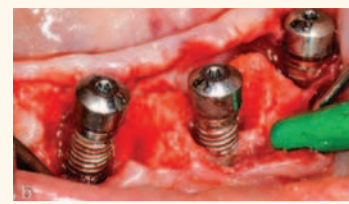


Figure 4. Post-op intra-oral photo at 6 months after therapy

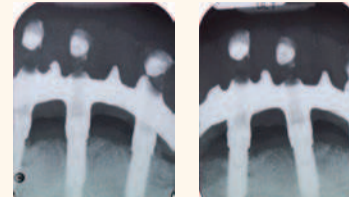


Figure 5. Post-op radiographs at 3 months after therapy.

Scientific World Journal 2015;2015, 11. Drago L, Del Fabbro M, Bortolin M, Vassena C, De Vecchi E, Taschieri S. Biofilm removal and antimicrobial activity of two different airpolishing powders: an in vitro study. J Periodontol 2014;85:e363-e369 [DOI](#)

Specialist Periodontist, Australia
BDS (Adel), DClinDent (Perio) (Syd), MRACDS (Perio)

Dr Vo is a Specialist Periodontist. He obtained his BDS dental degree from the University of Adelaide and then went on to receive a Doctor of Clinical Dentistry in Periodontics from the University of Syd-

ney. He has been awarded membership of the Royal Australasian College of Dental Surgeons as well as separate research grants in the fields of periodontology and craniofacial biology.

Working in private practice in Sydney since 2009, Dr Vo has also been a visiting clinical demonstrator for the DMD program at the University of Sydney. He is a member of the Australian and New Zealand Academy of Periodontists and the International Team for Implantology, speaks at conferences nationally and lectures on topics including the advanced and latest concepts in the management of periodontal diseases.



Celtra® Duo

Zirconia-Reinforced Lithium Silicate (ZLS) Block

Developed to make a difference

Celtra Duo (ZLS) is the one and only material block that provides you with an unsurpassed level of freedom, control, and workflow flexibility, resulting in a final restoration in which to have complete confidence with respect to the clinical, functional, and esthetic outcomes. Restorations made with Celtra Duo (ZLS) possess a chameleon effect, enabling them to blend in with surrounding teeth for a natural vitality and lifelike appearance.

For more information, visit celtra-dentsplysirona.com

THE DENTAL
SOLUTIONS
COMPANY™

Dentsply
Sirona