

Ulcerative Lichen Planus in childhood.

Case study

By Dr. Chiyadu Padmini, MDS, Dr. K.Y. Yellamma Bai, MDS, Dr. Vinil Chaitanya, MDS, Dr. M. Shilpa Reddy, MDS

Abstract

Lichen planus (LP) is a chronic inflammatory mucocutaneous condition which is relatively common in adults but rarely affects children. The present study is on report an unusual case of ulcerative oral LP involving the dorsum of tongue in 12 year old boy. Patient complained of painful oral lesion on the tongue which was burning in nature and obstructing talking and eating spicy foods. On intra oral examination, a white ulcerative lesion on the dorsum of tongue was observed. Diagnosis was made based on clinical examination and histopathological features. We instituted local treatment and patient responded well to the treatment. Although rarely reported in childhood, lichen planus should be considered in a differential diagnosis of hyperkeratotic, reticular and ulcerative lesions of the oral mucosa in children. Keywords: Oral lichen planus (OLP), childhood, ulcer.

Introduction

Lichen planus (LP) is an autoimmune, chronic, inflammatory disease that affects mucosal and cutaneous tissues. The exact etiology of LP is unknown, but it is believed to result from an abnormal T-cell mediated immune response in which basal epithelial cells are recognized as foreign because of changes in the antigenicity of their cell surface. Oral lichen planus (OLP) is a common disease in the middle aged and elderly population, and has a prevalence of about 0.5% to 2%. In contrast, oral lichen planus in childhood (OLP) is rare and it was first reported in 1920's. Oral mucosal involvement in adult itself account for 0.5% to 19% while in children, it is very uncommon.²

The oral lesions are more pleomorphic than those of their cutaneous forms and subtypes are categorized as reticular, papular, plaque-like, atrophic, erosive, and bullous.³ The erosive form is extremely rare in children and few reports on this subject have been published in the literature.

Herewith, we are presenting a case of 12 year old boy having erosive lichen planus without cutaneous involvement, which responded very well to the treatment. This article is also reviews ulcerative oral lichen planus in children and emphasizes its diagnosis from other oral white and red lesions in children.

Case Report

A 12 year old boy reported to the Department of Pedodontics and Preventive dentistry, with the chief complaint of ulcer on his dorsum of the tongue which is causing burning sensation on consuming spicy foods from past 1 year.

There is no significant Medical history observed. On extra oral examination patient was normal. On intra oral examination, a single irregular red & white ulcerative lesion measuring approximately 2.5x1.0 cm in size, with granulation tissue at the centre surrounded by an inflammatory red border on the dorsum of the tongue noticed. There was a depapillation of filiform papillae in and around the lesion (Fig. 1). Oral hygiene of the patient was good without any dental restorations.

The differential diagnosis was lichen planus and lichenoid lesions. To exclude lichenoid reaction, we investigated his medical status and there was no history of any drug intake. The patient and his parents also denied any habits that may potentially cause oral mucosal ulcerations.

Histopathological examination showed hyperparakeratosis of stratified squamous epithelium and basal cell degeneration with dense band-linked lymphocytic infiltration at the epithelial-connective tissue interface (Fig. 2). Both clinical and histopathological features were consistent with ulcerative oral lichen planus.

Specific treatment for ulcerative OLP was topical 0.1% triamcinolone acetonide combined with 1% clotrimazole 3-5 times per day for the duration of one week. Topical anesthetic was given for the pain relief. First review of the patient after 15 days showed significant reduction in both symptoms and signs of the oral lesions. (Fig. 3) After 15 days, there is good prognosis in the recovery of ulcerative lichen planus. Erosive oral ulcerative oral lichen planus had completely healed at the end of 30 days. (Fig. 4) Patient was observed on periodic recall follow up.

Oral lichen planus in childhood (OLPc) is rare and only a few reports are available in the literature.⁴ Oral lichen planus can be divided into a hyperkeratotic (white) variant, commonly without symptoms, a reticular type with Wickham striae (often symmetrical), papular, and plaque-like types.

The atrophic/erythematous (red) variant and the erosive/ulcerative (yellow) variant often have persistent symptoms of pain or stinging aggravated during talking and eating spicy foods. These variants

may occur together in one patient or may transform one to another. The lesions were found more commonly on the buccal mucosa (often symmetrical), lateral margins of the tongue, gingiva and lips.

Whereas cutaneous LP is self-limiting, ulcerative OLP is chronic, rarely undergoes spontaneous remission. The family history of LP is more commonly positive in patients with LP in childhood than in adulthood. The exact cause of ulcerative OLP remains unknown, but an immune-mediated (T cell dependant) pathogenesis has been reported.

OLP in childhood was first described in 1920 and since then only few articles have been published and most of studies have suggested that childhood LP is more common in tropical countries like India.⁵ Sharma and Maheshwari reported 50 children with LP and with concomitant oral lesions in 15 of them and they stated that the oral mucosa seems to be less commonly involved in children with LP than in adults.⁶

Predisposing conditions such as graft-versus-host disease, active hepatitis, and hepatitis B immunization are rather frequently mentioned in these reports. Kumar V and Garg BR reported only one case had oral ulcerative lichen planus out of 25 patients with cutaneous lichen planus.⁷

The mean interval between vaccination and LP onset was three years, ranging between three months and 11 years. Handa and Sahoo reported 87 patients with childhood LP in India. Seven patients showed involvement of the oral mucosa and only one patient had oral ulcerative lichen planus without skin involvement.⁸

A 10 year retrospective study done by Ronald Laeijendecker et al, which comprised of 10,000 patients below 18 years, with a boy to girl ratio of 1:1 which have shown only 3 patients (0.03%) were diagnosed with oral lichen planus.⁹ A study done in United Kingdom by Alam and Hamburger in boys aged between 6- 14 years over a period of 20 years have proved only 6 boys been diagnosed with OLP and interestingly among 6 patients, 4 were Asians.¹⁰ In 1994, Scully et al reported 3 girls with OLP, one of whom was from Asian origin.¹¹ The difference in the prevalence of OLP in children (0.03%) versus OLP in adults (0.5-2%) is understood by less number of associated systemic diseases in children, auto-immune diseases, infections, drug usage and dental restorations in childhood, this

may reduce the risk for developing OLP in childhood.¹² Moreover the diagnosis of OLP may be missed due to irregular dental check-ups, lack of symptoms and ignorance by clinicians in diagnosing the condition.

The prognosis and the effect of treatment in OLP in children seem to be more favorable than in OLP in adults, which usually persists for many years in spite of intensive treatment and thorough investigation of associated factors. Malignant transformation of ulcerative OLP in adults is 0.07% to 5%, however malignant transformation of OLP in children is not documented in the literature till now.¹³

Conclusion

Oral lichen planus in childhood is rare, especially erosive form, diagnosis should be based on children presenting with ulcerative white lesion in oral cavity. The schedule of follow-up of OLP in children should be 7 days, 15 days and 30 days after diagnosis to assess healing. Patient should be reviewed twice a year for regular follow ups after complete progress of the present condition. However generally, the prognosis of oral lichen planus in childhood seems to be more favorable compared to adults.

References

- Patel S, Yeoman CM, Murphy R. Oral lichen planus in childhood. A report of 3 cases. *International Journal of Pediatric dentistry* 2005; 15: 118-22
- Eisen D. The clinical features, malignant potential and systemic associations of oral lichen planus: a study of 723 patients. *J Am Acad Dermatol* 2002; 46:207-214.
- Aguirre JM, Bagan JV, Rodriguez C, Jimenez Y, Martinez Conde R, Diaz de Rojas F. Efficacy of mometasone furoate microemulsion in the treatment of erosive-ulcerative oral lichen planus: pilot study. *J Oral Pathol Med.* 2004; 33:381e385.
- Cottoni F, Ena P, Tedde G, et al. Lichen planus in children: a case report. *Pediatr Dermatol* 1993; 10:132-135.
- Kanwar AJ, De D. Lichen planus in childhood: report of 100 cases. *Clin*

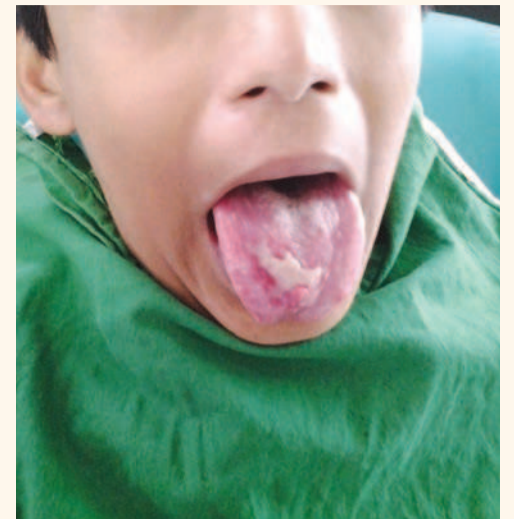


Fig. 1: Dorsum of Tongue showing Ulcerative lesion

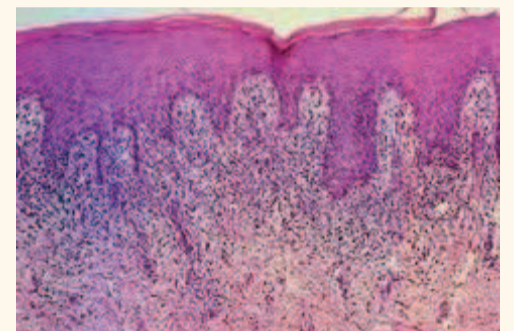


Fig. 2: Photomicrograph (5x magnification) of the Lesion

Exp Dermatol 2008;33: 423-7
6. Sharma, R. and Maheshwari, V. (1999) Childhood lichen planus: A report of fifty cases. *Pediatric Dermatology*, 16, 345-348. [DOI](#)

Editorial Note: The full reference list is available from the publisher.



Dr. Chiyadu Padmini, MDS
Senior Lecturer in the Department of Pedodontics and Preventive Dentistry, Malla Reddy Institute of Dental Sciences

MEDCARE WOMEN & CHILDREN HOSPITAL
Beside Manara Services Centre
Sheikh Zayed Road
Dubai, PO Box 215565

Dr. K. Yellamma Bai, MDS
Principal, Professor and Head of the Department of Pedodontics and Preventive dentistry, Malla Reddy College of Dental Sciences for Women

Dr. Vinil Chaitanya, MDS
Senior lecturer in the Department of Oral Medicine and Radiology, Malla Reddy Institute of Dental Sciences

Dr. M. Shilpa Reddy, MDS
Reader in the Department of Conservative Dentistry and Endodontics, Malla Reddy Institute of Dental Sciences.

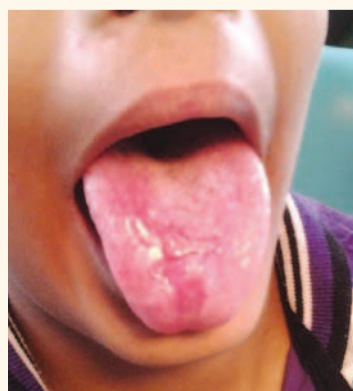

Fig. 3: Mid treatment (15th day of treatment) showing reduction in size & healing of the ulceration

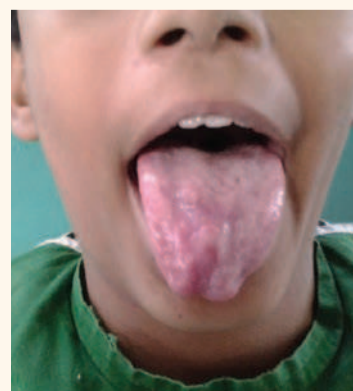


Fig. 4: Complete healing of ulcer on Tongue (after 30 days of treatment)

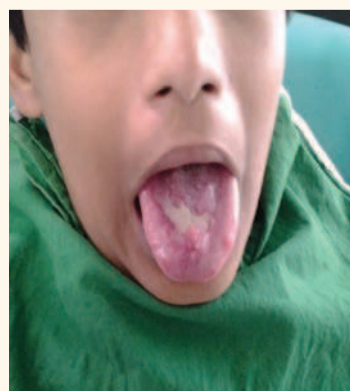


Fig. 5: Pre treatment photograph

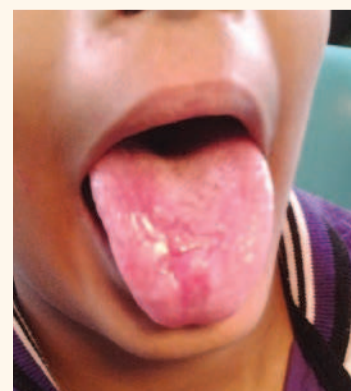


Fig. 6: Mid treatment photograph




Fig. 7: Post treatment photograph